The Veterinary Journal 295 (2023) 105987

Contents lists available at ScienceDirect

The Veterinary Journal

journal homepage: www.elsevier.com/locate/tvjl

Evaluation of a new smartphone-based digital stethoscope featuring phonocardiography and electrocardiography in dogs and cats

T. Vezzosi *, L. Alibrandi, G. Grosso, R. Tognetti

Department of Veterinary Sciences, University of Pisa, via Livornese lato monte, San Piero a Grado, 56122 Pisa, Italy

ARTICLE INFO

Keywords:
Atrial fibrillation
Cardiac auscultation
Digital stethoscope
Gallop sound
Phonocardiography

ABSTRACT

This study assessed a new smartphone-based digital stethoscope (DS) featuring simultaneous phonocardiographic and one-lead electrocardiogram (ECG) recording in dogs and cats. The audio files and ECG traces obtained by the device were compared with conventional auscultation and standard ECG. A total of 99 dogs and nine cats were prospectively included. All cases underwent conventional auscultation using an acoustic stethoscope, standard six-lead ECG, standard echocardiography and recordings with the DS. All the audio recordings, phonocardiographic files and ECG traces were then blind reviewed by an expert operator. The agreement between methods was assessed using Cohen's kappa and the Bland-Altman test. Audio recordings were considered interpretable in 90% animals. Substantial agreement was found in the diagnosis of heart murmur ($\kappa = 0.691$) and gallop sound ($k = 0.740$). In nine animals with an echocardiographic diagnosis of heart disease, only the DS detected a heart murmur or gallop sound. ECG traces recorded with the new device were deemed interpretable in 88 % animals. Diagnosis of heart rhythm showed moderate agreement in the identification of atrial fibrillation ($k = 0.596$). The detection of ventricular premature complexes and bundle branch blocks revealed an almost perfect agreement ($k = 1$). Overall, the DS showed a good diagnostic accuracy in detecting heart murmurs, gallop sounds, ventricular premature complexes and bundle branch blocks. A clinically relevant overdiagnosis of atrial fibrillation was found but without evidence of false negatives. The DS could represent a useful screening tool for heart sound abnormalities and cardiac arrhythmias..

1. Introduction

Cardiac auscultation is used for the early detection of heart disease. The reliability of cardiac auscultation depends mainly on the skill, competence and listening ability of the physician (Chowdhury et al., 2019; Joshi et al., 2021). Due to the variation in sensitivity of the human ear, some sounds may not be audible due to the low frequencies (Aumann and Emanetoglu (2019)). This limitation of conventional acoustic stethoscopes has led to the emergence of advanced electronic devices, such as digital stethoscopes (DS; Swarup and Makaryus (2018)). Digital stethoscopes have been developed for both human and veterinary medicine, especially because of their promising characteristics for telemedicine, teaching and cardiologic monitoring over time.

Several types of sensor-based DSs also equipped with phonocardiograms have been used in both human (Tavel, 2006; Noponen et al., 2007; Germanakis et al., 2008) and veterinary studies (Höglund et al., 2007; Ljungvall et al., 2009; Vörös et al., 2011; Vörös et al., 2012; Blass, et al., 2013; Szilvási et al., 2013; Balogh et al., 2021). Digital sound recording and phonocardiography in dogs with heart murmurs were described by Vörös et al. in 2011. Furthermore, it was shown that digital phonocardiography significantly improves the diagnostic accuracy of observers in the detection and characterization of cardiac murmurs (Szilvási et al., 2013). To enhance the usefulness of phonocardiography, it is often combined with a simultaneous electrocardiographic (ECG) recording. Smartphone-based ECGs have been studied in both human (Walsh et al., 2014, Peritz et al., 2015; Wegner et al., 2020) and veterinary medicine (Kraus et al., 2016; Vezzosi et al., 2016; Vezzosi et al., 2018; Yaw et al., 2018; Bonelli et al., 2019; Huynh, 2019; Kraus et al., 2019; Vezzosi et al., 2019; Welch-Huston et al., 2020; Vitale et al., 2021).

The aim of this study was to evaluate a new smartphone-based DS featuring simultaneous phonocardiographic and one-lead ECG

Abbreviations: DS, Digital stethoscope; CS, Conventional stethoscope; Sp, Specificity; Se, Sensitivity; PPV, Positive predictive value; NPV, Negative predicting value; stECG, Standard ECG.

* Corresponding author.
E-mail address: tommaso.vezzosi@unipi.it (T. Vezzosi).

https://doi.org/10.1016/j.tvjl.2023.105987
Accepted 30 April 2023
Available online 2 May 2023

recording in dogs and cats, comparing the audio recordings and ECG tracings obtained by the device with a conventional auscultation and standard six-lead ECG.

2. Materials and methods

This was a prospective observational study performed at the Veterinary Teaching Hospital of the University of Pisa between December 2020 and December 2021. The sample consisted of dogs and cats with heart disease and/or cardiac arrhythmias and healthy animals that required cardiology evaluation for cardiologic screening or preanesthetic evaluation. The study protocol was reviewed and approved by the Institutional Welfare and Ethics Committee of the University of Pisa (Authorization number: 53/2020; Date of approval: 11 December 2020).

The device tested in the study was the Eko DUO ECG + Digital Stethoscope (Eko Devices Inc.). The sound volume of the device was set to half of its scale and the extended mode was used as a filter. Dogs and cats were not shaved, only alcohol was applied to the left precordial area in order to increase the contact and transmission of the electrical signal.

The device was positioned with the microphone and the electrodes in a cranio-ventral direction and the portion with the output of the earphones in caudo-dorsal direction with an angle of about 30° at the level of the left precordial area (Fig. 1).

Each animal was subjected to cardiac auscultation with a conventional stethoscope (CS; 3 M Littmann Classic II, Littmann) and then auscultation and recording with the DS by a board-certified cardiologist (T.V.) using the Eko application on an iPhone 11Pro. In addition, each animal underwent a standard six-lead ECG (MAC 1600, General Electric) and standard echocardiography (Aplio 300, Canon). For the standard ECG, the following settings were used: sampling frequency of 1000 Hz for acquisition, a 100 Hz low-pass filter and a 0.3–0.5 Hz high-pass filter to decrease respiratory noise interference (Hinchcliff et al.,1997; Carnabuci et al., 2019). At the end of the DS recording, the traces (audio, phonocardiography and ECG) were saved on the smartphone application and automatically stored online.

When all the cases had been collected, a blinded analysis of each recording was performed by a board-certified cardiologist (T.V.). The analysis of the recordings consisted of listening to the audio tracks using headphones and the simultaneous analysis of the phonocardiographic traces from the online database (Figs. 2, 3 and 4). The audio tracks were randomly selected by a second operator (L.A.), who also guaranteed the blind analysis. The following data were assessed for each audio recording: audio recording quality (impossible to assess, acceptable for interpretation, excellent quality), presence of a murmur (yes/no), and presence of gallop sound (yes/no).

The ECG traces acquired with the DS were exported to PDF and printed via the dedicated website of the device. The ECGs obtained by standard six-lead ECGs were digitally saved on the computer as PDFs and then printed. All ECG traces were printed at a paper speed of 25 mm/s and an amplitude of 10 mm/mV. All traces were analyzed by an individual operator (T.V.) assessing: P wave (ms), PQ interval, QRS complex and QT interval duration (ms), and electrocardiographic diagnosis.

2.1. Statistical analysis

Only those cases in which the quality of the audio track and the ECG trace was considered acceptable were included in the statistical analysis, which was performed using commercially available software (GraphPad Prism). The Shapiro-Wilk test was used to determine the normality of the data distribution. As most of the data were not normally distributed they are reported as the median (range). Cohen's κ was used to calculate the agreement between CS findings (reference method) and the re-listening to DS-recorded traces, as well as for the agreement between standard ECG reference method) and the new device ECG tracings for the electrocardiographic diagnosis. The agreement was interpreted as follows: $\kappa < 0$ none; 0.00 – 0.20 slight; 0.21 – 0.40 fair; 0.41 – 0.6 moderate; 0.61 – 0.80 substantial; 0.81 – 1.00 almost perfect (Landis and Koch, 1977). The agreement between standard ECG and DS ECG tracings for numerical data were assessed using the Bland Altman plot. Lastly, the diagnostic accuracy was expressed using sensitivity, specificity, positive predictive value and negative predictive value.

3. Results

A total of 108 cases were included in the study, comprising 99 dogs (20 Mixed breed, 10 Labrador retrievers, eight Cavalier King Charles spaniels, seven Dachshunds, six Golden retrievers, five Boxers, five Chihuahuas, three Jack Russell terriers, three Miniature Pinschers, two Great Danes, two French bulldogs, two English bulldogs, two Pugs, two Dobermans, two Spanish greyhounds, two Romanian water dogs, two Rottweilers, one Poodle, one Beagle, one Bolognese dog, one Border collie, one Greater Swiss mountain dog, one Bull terrier, one Cocker spaniel, one Maltese dog, one German shepherd, one English pointer,

Fig. 1. The device was positioned with the microphone and the electrodes in a cranio-ventral direction and the portion with the output of the earphones in caudo-dorsal direction with an angle of about 30° at the level of the left precordial area.

Fig. 2. Phonocardiographic trace with relative ECG obtained by the digital stethoscope in a healthy dog.

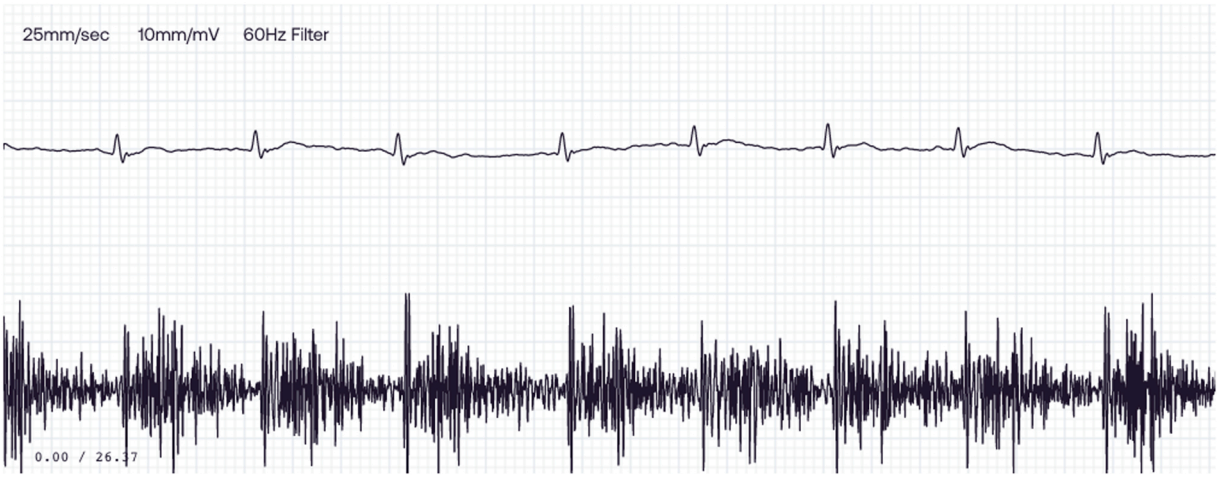

Fig. 3. Phonocardiographic trace with relative ECG obtained by the digital stethoscope in a dog with patent ductus arteriosus presenting with a continuous murmur.

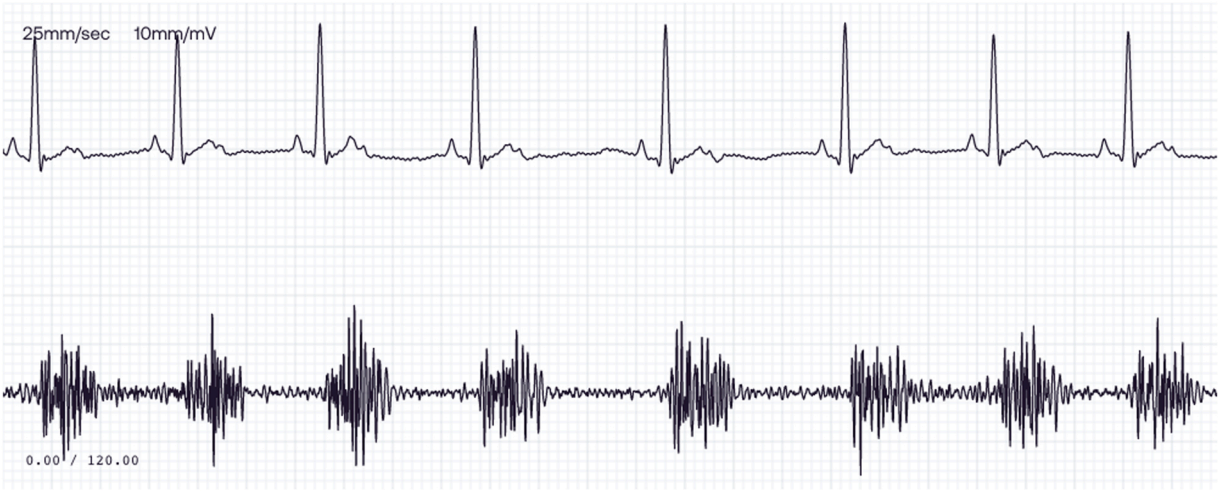

Fig. 4. Phonocardiographic trace with relative ECG obtained by the digital stethoscope in a dog with severe myxomatous mitral valve disease presenting with a systolic murmur.

one Bloodhound, one Shiba Inu, one Spitz, one West Highland white terrier, one Whippet, one Yorkshire terrier) and nine cats (seven Domestic shorthairs, one Main Coon and one Birman).

The canine sample included 42 females and 66 males, with a median age of 8 years (range, 0.5–17 years) and median body weight of 14.1 kg (range, 1.4–66 kg).

The feline sample included one female and eight males, with a median age of 11 years (range, 1–17 years), and median body weight of 5.4 kg (range, 3–6.4 kg).

Considering all the study animals, 31 animals (28.7 %) were healthy and the remaining 77 animals (71.3 %) had heart disease. The latter included aortic or sub-aortic stenosis in five animals (four dogs and one cat), patent ductus arteriosus in three dogs, ventricular septal defect in three dogs, pulmonary stenosis in two dogs, tricuspid dysplasia in one dog, myxomatous mitral valve disease in 50 animals, hypertrophic cardiomyopathy in three cats, dilated cardiomyopathy in two cats, pulmonary hypertension in eight animals (three cats and five dogs).

According to the standard ECG, 88 animals presented in sinus rhythm, seven animals presented with atrial fibrillation, 11 animals had ventricular premature complexes, and six animals had a bundle branch block (five left bundle branch block and one right bundle branch block).

3.1. Cardiac auscultation findings

Of 108 animals, 11 dogs were excluded from this analysis because the recorded audio tracings were not deemed to be interpretable because of noise due to the animals' behavior (anxiety, biting, vocalizing), or rubbing noises caused by the coat in panting dogs. Audio recording quality was considered acceptable for interpretation in 58 animals and of excellent quality in 39 animals.

The sample considered for this analysis therefore included 97 animals, of which 40 animals did not present with a cardiac murmur, and the remaining 57 had a cardiac murmur according to auscultation with the CS. Based on relistening to the audio traces recorded with the DS, substantial agreement was found in the detection of a murmur (k = 0.691; 96 % sensitivity and 70 % specificity; Table 1).

In two cases a murmur was detected by CS and not by DS. In 12 animals, the DS detected heart murmurs that were not detected using the CS: in seven out of 12 animals (58 %) heart disease was diagnosed by echocardiography (three dogs with mild-to-moderate pulmonary hypertension, two dogs with mild myxomatous mitral valve disease, one dog with mild subaortic stenosis and one cat with dilated cardiomyopathy), while the remaining five out of 12 dogs (42 %) had normal echocardiographic findings with a murmur of slight entity and duration.

The detection of gallop sound showed substantial agreement between CS and DS (k = 0.740), with 100 % sensitivity and 98 % specificity. In two cats, gallop sound was detected only by DS, and in both cases an underlying heart disease was diagnosed by echocardiography (one cat with hypertrophic cardiomyopathy, and one cat with dilated cardiomyopathy).

Table 1
Auscultatory findings regarding the presence of heart murmur and gallop sound based on direct auscultation with the conventional stethoscope (CS) and the relistening of audio files obtained with the digital stethoscope (DS). The calculated specificity (Sp), sensitivity (Se), positive predictive value (PPV), negative predictive value (NPV) and Cohen's k value (k) are also shown in the table.

Analysis				
Murmur		CS		
	YES	NO		
DS	YES	55	12	PPV = 82 %
	NO	2	28	NPV = 93 %
		Se = 96 %	Sp = 70 %	k = 0.691
Gallop sound		CS		
	YES	NO		
DS	YES	3	2	PPV = 60 %
	NO	0	92	NPV = 100 %
		Se = 100 %	Sp = 98 %	k = 0.740

3.2. ECG results

Of the 108 animals included, 13 ECG traces were judged as non-interpretable because of the presence of noise preventing the accurate recognition of QRS complexes. The sample thus considered for this analysis included 95 animals. No clinically significant differences were found in ECG measurements between the standard ECG and the DS ECG (Table 2; Fig. 5). With regard to the diagnosis of atrial fibrillation, the agreement between CS and DS was moderate with k = 0.596, with a sensitivity of 100 % and a specificity of 91 % (Table 3; Fig. 6A). In eight animals the DS detected atrial fibrillation where it was not present on standard ECG because of the presence of noise on the isoelectric line which limited the identification of P waves. Regarding the detection of ventricular premature complexes and bundle branch blocks (Fig. 6B), a perfect agreement was found between CS and DS (k = 1).

4. Discussion

The new device showed a good diagnostic accuracy in the detection of heart murmurs, gallop sound and arrhythmias in dogs and cats. The detection of cardiac murmurs by listening to audio tracings recorded with the DS demonstrated an agreement with CS findings in 86 % animals, with a significant efficacy in excluding the presence of a murmur based on a sensitivity of 96%. Based on the present study, we believe that the assessment of the phonocardiographic tracings during the listening of audio tracings can help operators to verify the presence/absence of a murmur. This finding is also supported by a recent study by Balogh et al. (2021) on a DS, in which phonocardiography was considered as a valuable aid when listening to audio traces.

In the present study, in seven animals presenting with an underlying cardiac disease, the DS detected a heart murmur that was not identified using the CS. These findings demonstrate the reliability of cardiac auscultation with the DS for screening cardiac murmurs, and possibly suggest that in such cases the new device is more sensitive. However, the possible higher sensitivity of the DS could lead to an increase in the number of non-pathological murmurs (i.e. innocent or functional murmurs) detected by the device. Indeed, differently from CS, relistening to the audio tracing obtained with the DS led to the detection of non-pathological murmurs in five dogs that presented with normal echocardiographic findings. Thus, further studies are warranted to verify these preliminary results and to possibly propose the DS for the remote assessment of cardiac auscultation in veterinary medicine, as already used in humans (Onweni et al., 2021).

Regarding the identification of gallop sound, the auscultatory findings obtained with DS were in agreement with the CS, with a very good diagnostic accuracy (sensitivity 100 % and specificity 98 %). These results are in disagreement with those reported by Blass et al. 2013 who described the ability of a different DS in detecting gallop sound in cats, reporting a sensitivity of 34 % and specificity of 92 % when used by an

Table 2
Median and interquartile ranges of the values obtained with standard electrocardiogram (ECG) and digital stethoscope (DS) ECG, and Bland-Altman test results regarding the comparison between the two methods.

	Standard ECG	DS ECG	Bias	95% Limits of agreement
P (ms)	40 (30 – 40)	40 (30 – 40)	-3	− 13, + 7
PQ (ms)	100 (80 – 100)	90 (80 – 100)	-5	− 32, + 23
QRS (ms)	50 (40 – 60)	50 (50 – 60)	-4	− 21, + 14
QT (ms)	200 (180 – 200)	200 (180 – 200)	-8	− 35, + 19

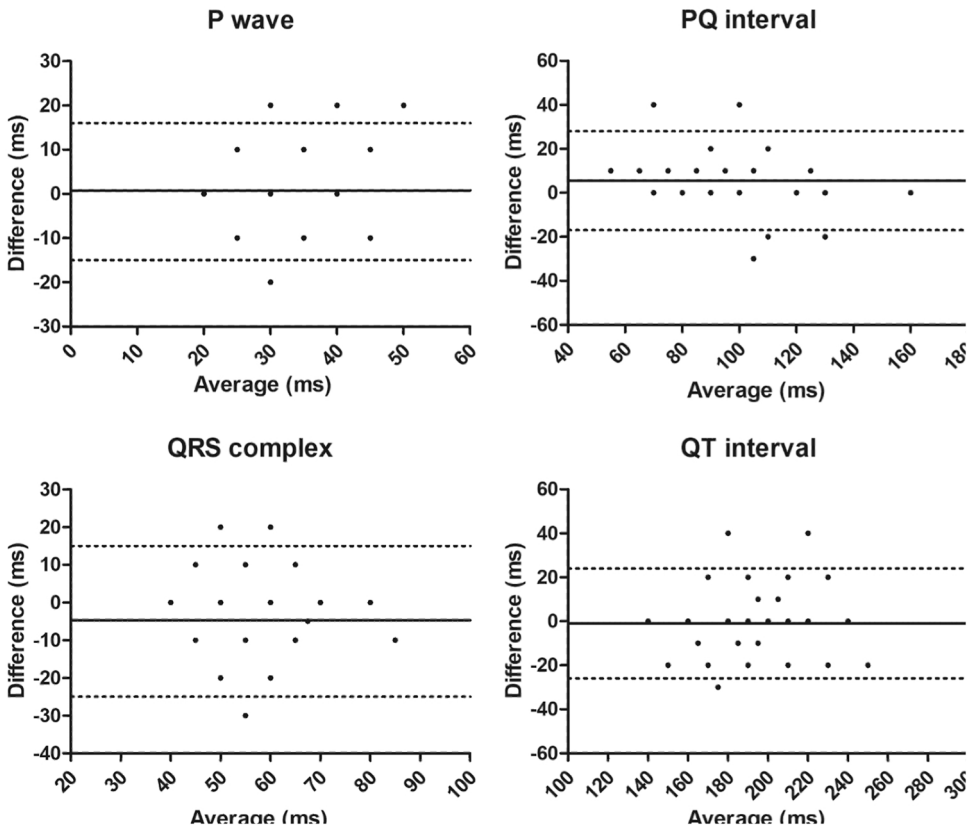

Fig. 5. Bland-Altman plots of the difference in electrocardiographic measurements (P wave duration, PQ interval, QRS complex duration, QT interval) between standard ECG and ECG trace recorded with the digital stethoscope.

Table 3
Electrocardiographic findings regarding atrial fibrillation (AF), premature complexes and bundle branch blocks according to six-lead standard electrocardiography (stECG) and one-lead electrocardiographic trace obtained with the digital stethoscope (DS). The calculated specificity (Sp), sensitivity (Se), positive predictive value (PPV), negative predictive value (NPV) and Cohen's k value (k) are also shown in the table.

Analysis				
			stECG	
Rhythm			AF	Sinus
	DS	AF	7	8
		Sinus	0	80
			Se = 100 %	Sp = 91 %
			stECG	
Premature complexes			YES	NO
	DS	YES	11	0
		NO	0	84
			Se = 100 %	Sp = 100 %
			stECG	
Bundle branch blocks			YES	NO
	DS	YES	6	0
		NO	0	89
			Se = 100 %	Sp = 100 %

experienced cardiologist. However, it should be noted that the cited study used a DS of an earlier generation than the one we used, which could explain the differences in the results. Interestingly, in two cats in our study, only the DS was able to detect gallop sound, and the assessment of the phonocardiographic tracings helped in this detection.

Regarding the electrocardiographic performance of the new device, the ECG tracings were judged to be interpretable in 88% cases. This is in agreement with findings reported in human and veterinary medicine, where ECG traces obtained with one-lead smartphone ECG devices were considered interpretable in 87–99.6% human and veterinary patients (Saxon, 2013; Nguyen et al., 2015; Garabelli et al., 2017; Vezzosi et al., 2018). In our experience, the main limitations in acquiring good quality ECG racings with the DS is the lack of compliance of some dogs, the low wave amplitude in cats and the substantial undercoat in some animals. In addition, movement or skin tremor can create artifacts on the isoelectric line which sometimes make the recordings too difficult to analyze. This type of artifact was also detected in the study conducted on dogs with other smartphone ECG devices, decreasing the quality of the recorded traces (Kraus et al. 2016; Vezzosi et al., 2016).

The DS was moderately reliable in the detection of atrial fibrillation (Table 3). In fact, there was an overdiagnosis of atrial fibrillation in some cases (i.e., false positives). These results are in agreement with those obtained with other smartphone ECG devices both in human and veterinary medicine, reporting a sensitivity of 94–100 % and a specificity of 72–98 % in the diagnosis of atrial fibrillation (Lau et al., 2013; Haberman et al., 2015; Vezzosi et al., 2016; Baman et al., 2022). In our sample, there were eight cases of false positives, because of oscillations on the isoelectric line which made it difficult to identify P waves or the P waves had too small amplitude to be visible on the one-lead smartphone tracing. Since atrial fibrillation is one of the most common arrhythmias in dogs, the sensitivity of the DS in detecting this arrhythmia means it can identify or monitor atrial fibrillation. However, the not perfect specificity suggests the need for confirmation of atrial fibrillation with a standard six-lead ECG.

Lastly a perfect agreement between the DS's ECG and standard ECG was found for the detection of ventricular premature complexes, in line with previous studies (Kraus et al., 2016, Vezzosi et al., 2016). The same perfect agreement was found for bundle branch blocks.

The present study has some limitations. Firstly, the re-listening of the audio files and the assessment of smartphone ECG traces were

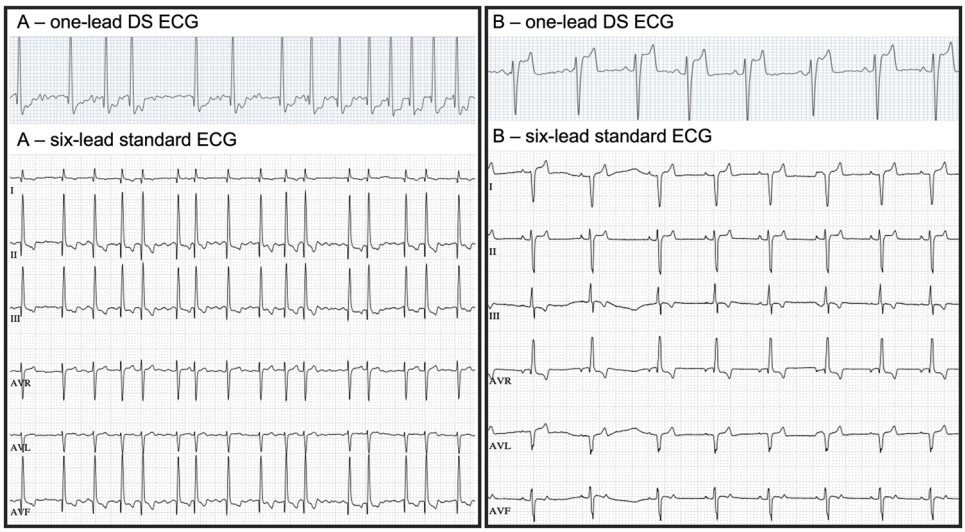

Fig. 6. Electrocardiographic traces obtained with the digital stethoscope in a dog with atrial fibrillation (A) and in a dog with right bundle branch block (B).

performed by only one operator with substantial experience in veterinary cardiology. The results obtained in our study might thus have been different using multiple operators with different levels of experience. Further studies evaluating inter-operator variability in the interpretation of audio recordings and ECG traces produced with the new device are thus needed. Secondly, the audio files were relistened to by an operator highly experienced in cardiology but with less experience in the analysis of audio files obtained by smartphone-based DS. Studies performed in human medicine show that the accuracy of cardiac murmur characterization improves after a learning period, consisting of both the application of the DS during the clinical examination and the relistening of the audio records generated (Germanakis et al., 2008; Mahnke et al., 2008). The third limitation was the inability to compare the intensity of murmurs between DS and CS. In fact, the use of audio recordings does not allow the assignment of a murmur intensity according to commonly used scales, since the thrill cannot be identified and the digital sound intensity of murmurs is not standardized. Therefore, further studies comparing direct auscultation with DS and CS would be particularly interesting. In addition, the results of the present study regarding the identification of arrhythmias with the DS suggest the possible utility of the device for an electrocardiographic screening; however, based on the low number of arrhythmic cases included, further studies verifying these preliminary results are needed, especially for the detection of atrial fibrillation. Lastly, the low number of feline subjects included limits the applicability to the general feline population of the diagnostic performance of the DS found in the present study.

5. Conclusions

The DS showed a good diagnostic accuracy in the detection of heart murmurs, gallop sound, ventricular premature complexes and branch blocks in dogs and cats. A clinically relevant overdiagnosis of atrial fibrillation was found but without evidence of false negatives. Good reliability for the detection of heart murmur and gallop sound was also found when supported by the phonocardiographic trace. However, given the high sensitivity of the microphone and electrodes, it may be difficult to acquire good traces in noncompliant animals; in about 10% animals in our study it was not possible to perform statistical analysis.

This new device could represent a useful screening tool for heart sound abnormalities and cardiac arrhythmias, also suitable for development of veterinary telemedicine and cardiac auscultation teaching. However, for detection of arrhythmias, a standard six-lead ECG is always recommended for a definitive diagnosis.

Conflict of interest statement

None of the authors has any financial or personal relationships that could inappropriately influence or bias the content of the paper.

References

Aumann, H.M., Emanetoglu, N.W., 2019. Stethoscope with digital frequency translation for improved audibility. Healthcare Technology Letters 6, 143–146.

Balogh, M., Koch, F., Siver, L., Krima, A., Vörös, K., 2021. Digital phonocardiography of cardiac arrhythmias in dogs – preliminary experiences. Acta Veterinaria Hungarica 69, 116–124.

Baman, J.R., Mathew, D.T., Jiang, M., Passman, R.S., 2022. Mobile health for `arrhythmia diagnosis and management. Journal of General Internal Medicine 37, 188–197.

Blass, K.A., Schober, K.E., Bonagura, J.D., Scansen, B.A., Visser, L.C., Lu, J., Smith, D.N., Ward, J.L., 2013. Clinical evaluation of the 3M Littmann electronic stethoscope model 3200 in 150 cats. Journal of Feline Medicine and Surgery 15, 893–900.

Bonelli, F., Vezzosi, T., Meylan, M., Nocera, I., Ferrulli, V., Buralli, C., Meucci, V., Tognetti, R., 2019. Comparison of smartphone-based and standard base-apex electrocardiography in healthy dairy cows. Journal of Veterinary Internal Medicine 33, 981–986.

Carnabuci, C., Tognetti, R., Vezzosi, T., Marchesotti, F., Patata, V., Domenech, O., 2019. Left shift of the ventricular mean electrical axis in healthy Doberman Pinschers. The Journal of Veterinary Medical Science 81, 620–625.

Chowdhury, M.E.H., Khandakar, A., Alzoubi, K., Mansoor, S., Tahir, A.M., Ibne Reaz, M. Bin, Emadi, N.Al, 2019. Real-time smart-digital stethoscope system for heart diseases monitoring. Sensors 19, 2781.

Garabelli, P., Stavrakis, S., Po, S., 2017. Smartphone-based arrhythmia monitoring. Current Opinion in Cardiology 32, 53–57.

Germanakis, I., Dittrich, S., Perakaki, R., Kalmanti, M., 2008. Digital phonocardiography as a screening tool for heart disease in childhood. Acta Paediatrica 97, 470–473.

Haberman, Z.C., Jahn, R.T., Bose, R., Tun, H., Shinbane, J.S., Doshi, R.N., Chang, P.M., Saxon, L.A., 2015. Wireless smartphone ECG enables large-scale screening in diverse populations. Journal of Cardiovascular Electrophysiology 26, 520–526.

Hinchcliff, K.W., Constable, P.D., Farris, J.W., Schmidt, K.E., Hamlin, R.L., 1997. Electrocardiographic characteristics of endurance-trained Alaskan sled dogs. Journal of the American Veterinary Medical Association 211, 1138–1141.

Höglund, K., Ahlstrom, C.H., Häggström, J., Ask, P.N., Hult, P.H., Kvart, C., 2007. Time-frequency and complexity analyses for differentiation of physiologic murmurs from heart murmurs caused by aortic stenosis in Boxers. American Journal of Veterinary Research 68, 962–969.

Huynh, M., 2019. Smartphone-based device in exotic pet medicine. The Veterinary Clinics of North America Exotic Animal Practice 22, 349–366.

Joshi, S.S., Patil, M.R., Kanawade, N.P., More, A.P., 2021. Bluetooth-based wireless digital stethoscope. In: Proceedings of the International Conference on Emerging Smart Computing and Informatics (ESCI) 2021, Pune, India, 5th-7th March 2021, pp.197–202.

Kraus, M.S., Gelzer, A.R., Rishniw, M., 2016. Detection of heart rate and rhythm with a smartphone-based electrocardiograph versus a reference standard electrocardiograph in dogs and cats. Journal of the American Veterinary Medical Association 249, 189–194.

Kraus, M.S., Rishniw, M., Divers, T.J., Reef, V.B., Gelzer, A.R., 2019. Utility and accuracy of a smartphone-based electrocardiogram device as compared to a standard base-apex electrocardiogram in the horse. Research in Veterinary Science 125, 141–147.

Landis, J.R., Koch, G.G., 1977. The measurement of observer agreement for categorical data. Biometrics 33, 159–174.
Lau, J.K., Lowres, N., Neubeck, L., Brieger, D.B., Sy, R.W., Galloway, C.D., Albert, D.E., Freedman, S.B., 2013. iPhone ECG application for community screening to detect silent atrial fibrillation: a novel technology to prevent stroke. International Journal of Cardiology 165, 193–194.
Ljungvall, I., Ahlstrom, C., Höglund, K., Hult, P., Kvart, C., Borgarelli, M., Ask, P., Häggström, J., 2009. Use of signal analysis of heart sounds and murmurs to assess severity of mitral valve regurgitation attributable to myxomatous mitral valve disease in dogs. American Journal of Veterinary Research 70, 604–613.
Mahnke, C.B., Mulreany, M.P., Inafuku, J., Abbas, M., Feingold, B., Paolillo, J.A., 2008. Utility of store-and-forward pediatric telecardiology evaluation in distinguishing normal from pathologic pediatric heart sounds. Clinical Pediatrics 47, 919–925.
Nguyen, H.H., Van Hare, G.F., Rudokas, M., Bowman, T., Silva, J.N., 2015. SPEAR trial: smartphone pediatric electrocardiogram trial. PLOS One 10, e0136256.
Noponen, A.L., Lukkarinen, S., Angerla, A., Sepponen, R., 2007. Phono-spectrographic analysis of heart murmur in children. BMC Pediatrics 7, 23.
Onweni, C.L., Venegas-Borsellino, C.P., Treece, J., Turnbull, M.T., Ritchie, C., Freeman, W.D., 2021. The power of mobile health: the girl with the gadgets in Uganda. Mayo Clinic Proceedings Innovations, Quality and Outcomes 5, 486–494.
Peritz, D.C., Howard, A., Ciocca, M., Chung, E.H., 2015. Smartphone ECG aids real time diagnosis of palpitations in the competitive college athlete. Journal of Electrocardiology 48, 896–899.
Saxon, L.A., 2013. Ubiquitous wireless ECG recording: a powerful tool physicians should embrace. Journal of Cardiovascular Electrophysiology 24, 480–483.
Swarup, S., Makaryus, A.N., 2018. Digital stethoscope: technology update. Medical Devices: Evidence and Research 11, 29–36.
Szilvási, V., Vörös, K., Manczur, F., Reiczigel, J., Novák, I., Máthé, A., Fekete, D., 2013. Comparison of traditional and sensor-based electronic stethoscopes in beagle dogs. Acta Veterinaria Hungarica 61, 19–29.
Tavel, M.E., 2006. Cardiac auscultation. A glorious past – and it does have a future! Circulation 113, 1255–1259.
Vezzosi, T., Buralli, C., Marchesotti, F., Porporato, F., Tognetti, R., Zini, E., Domenech, O., 2016. Diagnostic accuracy of a smartphone electrocardiograph in dogs: comparison with standard 6-lead electrocardiography. The Veterinary Journal 216, 33–37.
Vezzosi, T., Sgorbini, M., Bonelli, F., Buralli, C., Pillotti, M., Meucci, V., Tognetti, R., 2018. Evaluation of a smartphone electrocardiograph in healthy horses: comparison with standard base-apex electrocardiography. Journal of Equine Veterinary Science 67, 61–65.
Vezzosi, T., Tognetti, R., Buralli, C., Marchesotti, F., Patata, V., Zini, E., Domenech, O., 2019. Home monitoring of heart rate and heart rhythm with a smartphone-based ECG in dogs. The Veterinary Record 184, 96.
Vitale, V., Vezzosi, T., Tognetti, R., Fraschetti, C., Sgorbini, M., 2021. Evaluation of a new portable 1-lead digital cardiac monitor (eKuore) compared with standard base-apex electrocardiography in healthy horses. PLoS One 16, 1–11.
Vörös, K., Nolte, I., Hungerbühler, S., Reiczigel, J., Ehlers, J.P., Tater, G., Mischke, R., Zimmering, T., Schneider, M., 2011. Sound recording and digital phonocardiography of cardiac murmurs in dogs by using a sensor-based electronic stethoscope. Acta Veterinaria Hungarica 59, 23–35.
Vörös, K., Bonnevie, A., Reiczigel, J., 2012. Comparison of conventional and sensor-based electronic stethoscopes in detecting cardiac murmurs of dogs. Tierarztliche Praxis Ausgabe K: Kleintiere - Heimtiere 40, 103–111.
Walsh, J.A., Topol, E.J., Steinhubl, S.R., 2014. Novel wireless devices for cardiac monitoring. Circulation 130, 573–581.
Wegner, F.K., Kochhäuser, S., Ellermann, C., Lange, P.S., Frommeyer, G., Leitz, P., Eckardt, L., Dechering, D.G., 2020. Prospective blinded evaluation of the smartphone-based AliveCor Kardia ECG monitor for atrial fibrillation detection: the PEAK-AF study. European Journal of Internal Medicine 73, 72–75.
Welch-Huston, B., Durward-Akhurst, S., Norton, E., Ellingson, L., Rendahl, A., McCue, M., 2020. Comparison between smartphone electrocardiography and standard three- lead base apex electrocardiography in healthy horses. The Veterinary Record 187, e70.
Yaw, T.J., Kraus, M.S., Ginsburg, A., Clayton, L.A., Hadfield, C.A., Gelzer, A.R., 2018. Comparison of a smartphone-based electrocardiogram device with a standard six-lead electrocardiogram in the atlantic bottlenose dolphin (*Tursiops truncatus*). Journal of Zoo and Wildlife Medicine 49, 689–695.